

Nerve-Sparing Cryoablation for the Treatment of Primary Prostate Cancer: the Preliminary Report

Seong Choi

Department of Urology, College of Medicine, Kosin University, Busan, Korea

전립선암에 대한 신경보존 냉동제거수술요법 : 예비보고

최 성

고신대학교 의과대학 비뇨기과학교실

Background: To present a pilot study of nerve-sparing cryoablation for the treatment of primary prostate cancer.

Materials and Methods: Between 2008 and 2011, 9 patients underwent nerve-sparing cryoablation (unilateral 5, bilateral 4 patients). One neurovascular bundle (NVB) was spared on the side opposite the positive biopsy, and two NVBs were spared when indicated and possible. Just before the start of freezing, a 22-gauge spinal needle was placed into Denonvilliers fascia using a transperineal route, and normal saline was injected to separate the rectum from the prostate. The prostate-specific antigen (PSA) level was sampled every 3 months for the first 2 years and then every 6 months thereafter. Patients were considered to have a stable PSA if they had two consecutive PSA measurements without a rise.

Results: The follow-up was 40-months (19-66 months). All patients had stable PSA levels at last follow-up. Potency (defined as an erection sufficient to complete intercourse to the satisfaction of the patient) was maintained in 4 of 9 patients, 5 were potent with phosphodiesterase 5 inhibitors or intracavernosal injection.

Conclusions: Nerve-sparing cryoablation, in which one or two neurovascular bundle is spared, showed the possibility of preserving potency in most patients without compromising cancer control. These preliminary results warrant further study.

Key Words: Cancer, Cryoablation, Potency, Prostate

For the treatment of localized prostate cancer, radical prostatectomy (RP) is the standard treatment. By sparing the neurovascular bundles (NVBs), potency rates showed a rise from 1% to 2% of traditional RP to almost 70%.¹ Therefore nerve sparing RP became preferred

option clearly in young patients, and there has been a significant increase in last decades. Yet, there are significant limitations in nerve sparing RP. Reported potency rates of nerve-sparing RP showed a large range from 18%² to 94%.³ Nerve-sparing RP reported incon-

Corresponding Author : Seong Choi, Department of Urology, College of Medicine, Kosin University, 262, Kamcheon-ro, Seo-gu, Busan, 602-702, Korea
TEL: +82-51-990-6253 FAX: +82-51-990-3994 E-mail: schoi@ns.kosinmed.or.kr

Received : August 21, 2013
Revised : October 25, 2013
Accepted : December 16, 2013

tinence rates as high as 6%, and is also associated with significant operative morbidity such as blood loss or infection,³ and for positive margin rates, nerve-sparing RP showed 40%.^{4,5} In 1970s, open transperineal prostate cryoablation has begun as a treatment for prostate cancer, but did not perform increasingly.⁶ Again in 1993, percutaneous approach of prostate cryoablation, with the addition of ultrasound monitoring was introduced as a cure of primary prostate cancer.⁷ For the effective treatment, the total gland ablation has been targeted. Therefore, aggressive cryoablation to both NVBs and periprostatic tissue has a significant impact on sexual function. Cryoablation has the advantages of particular capability of repeat the procedure without morbidity.⁸ But the radiation therapy, especially brachytherapy, shows a decline in sexual function, protracted morbidity, and the emergence of late-onset morbidity. Impotence occurs frequently after cryoablation because of the proximity of the NVBs to the prostate. Impotency resolve overtime, because the NVBs that mediate potency are frozen but not destroyed (as with RP), regeneration of nerve may recover erectile function. A prospective study evaluated the quality of life (QOL) and sexuality before and after cryoablation.⁹ All patients who reported as potent pre-operatively showed complete loss of erectile function after cryoablation 6 weeks. But, 47% of patients achieved erections sufficient for intercourse either spontaneously or with assistance at 3 years. No late-onset morbidity was showed. In this report, the author present the results of “nerve-sparing” cryoablation with the aim of preserving patient’s potency, when cryoablation was applied to treat localized prosate cancer.

MATERIALS AND METHODS

Patient Selection

Between January 2008 and December 2011, 9 patients underwent nerve-sparing cryoablation (unilateral 5, bilateral 4 patients). The selection of patient is nearly the same as that for unilateral or bilateral nerve sparing RP, such as acceptable low probability of involvement in one or both NVBs. The patients were considered for nerve-sparing cryoablation, based on findings of biopsy, their cancer was confined to one lobe of the prostate and they were potent based on patient history and the potency maintenance was a primary concern of the patient. All patients were evaluated preoperatively by bone scan, MRI or CT scan and rectal examination to rule out metastasis or invasion to other organs. And there were no limitation of PSA level or Gleason score. Only prostate cancer patients confined into prostate were indicated to this nerve-sparing cryoablation. The usual cryosurgical informed consent was given. All patients receiving combined hormonal treatment before cryoablation stopped immediately after operation.

Clinical Procedure

The procedures of percutaneous prostate cryoablation are nearly the same as that originally described.⁷ In all cases, the urethral warming catheter was used. To accommodate the concept of nerve sparing and to increase the safety and efficacy of the cryoablation, following changes were made to the procedure:

1. 10-14 cryoprobes were used within the prostate for complete ablation of a targeted portion of the prostate within which the cancer is believed to be confined. The freezing extents were tailored to the individual patient and were determined by the clinical parameters of patients, including stage, Gleason grade, tumor location, and prostate specific antigen (PSA) level.
2. In unilateral nerve sparing cryoablation, the NVB was destroyed on the side of the patient’s tumor. Sparing

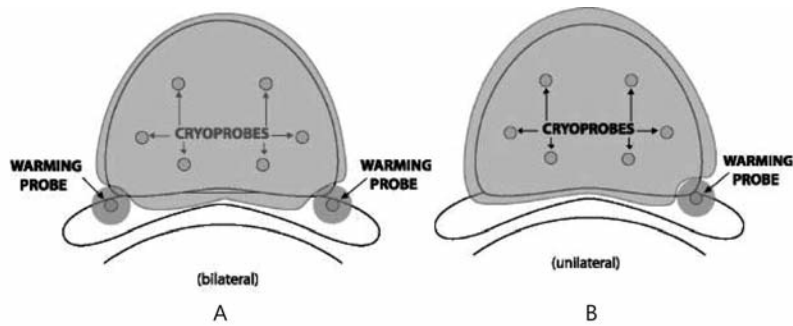


Fig. 1. A schematic of the cryoprobe and warming probe placement for A. bilateral nerve sparing cryoablation and B. unilateral nerve sparing cryoablation.

NVB on the side opposite the tumor was attempted, and two NVBs were spared when indicated and possible.

3. Cryoprobes were placed approximately 1 cm apart in the regions to be destroyed and within 5 mm of the prostatic capsule on the side of the cancer.
4. Temperature monitoring was carried out with thermocouples in critical locations such as posterior margin and the apex of the gland to ensure maintenance of non-ablative temperatures. Temperatures were monitored in the NVB opposite the tumor to prevent bun-

dle destruction.

5. Before freezing, a 22-gauge spinal needle was placed into Denonvilliers fascia using a transperineal approach. To separate the rectum from the prostate, normal saline was injected into the space.
6. An argon gas-based system was used to carry out the freezing using the 17-gauge cryoprobe and SeedNet Gold system (Galil Medical, Westbury, NY, USA), replacing the original liquid nitrogen freezing equipment.
7. Warming probes are placed in one or both neurovas-

TABLE 1. Patient characteristics

Age (yr)	Gleason Score	Preop.PSA (ng/mL)	Positive Cores(n)	Stage	Preop.TURP/HOLEP	Area frozen	Follow-up (mo)	Postop.PSA (ng/mL)	PSA stable	Change/Potency
68	7	16.06	1	T1c	No	Unilateral	71	0.07	Yes	Potent with PDE5I
61	6	9.78	1	T1c	No	Unilateral	68	1.0	Yes	Potent
58	4	10.44	4	T2a	No	Bilateral	68	0.84	Yes	Potent
58	7	5.7	2	T2a	No	Unilateral	36	0.2	Yes	Potent with ICI
52	5	3.70	1	T1c	No	Unilateral	39	0.17	Yes	Potent with ICI
58	7	3.2	1	T1c	Yes	Bilateral	21	0.04	Yes	Potent with ICI
65	7	3.00	1	T1c	Yes	Bilateral	21	0.09	Yes	Potent with ICI
58	6	4.56	4	T1c	No	Unilateral	20	0.013	Yes	Potent
46	6	9.33	2	T2a	No	Bilateral	19	0.4	Yes	Potent

PSA=prostate specific antigen, Stage=clinical T stage

TURP=transurethral resection of the prostate, HOLEP=holmium laser enucleation of the prostate,

PDE5I=phosphodiesterase 5 inhibitors, ICI=intracavernosal injection.

cular bundles using transrectal color Doppler ultrasonography and they are operated with helium gas throughout the procedure (Fig.1).

Patient Follow-up

Patients were stopped from combined hormonal treatment immediately after the cryoablation. The level of PSA was checked every 3 months for the first 2 years and then every 6 months. If the patients had two consecutive PSA determinations without a rise, they were considered to have a stable PSA level. Patients were followed up using questionnaire and telephone call. Patients were regarded as potent if erections are sufficient for vaginal penetration and were satisfied with their sexual functioning.

RESULTS

During 2008 and 2011, of 67 prostate cancer patients underwent cryoablation, 9 (13.4%) men have been underwent nerve sparing cryoablation. Therefore, the patients received nerve sparing cryoablation represented 13.4% of total patient population during that period. The follow-up ranged from 19 to 66 months (mean 40) (Table 1). All patients were potent preoperatively. Preoperative PSA level of all patients changed to have stable PSA levels at last follow-up (mean 40 months). The mean preoperative PSA level was 7.31 (3.00-16.06) ng/mL. The mean postoperative PSA level at last follow up was 0.31 (0.01-1.0) ng/mL. No patient required additional treatment including hormonal therapy after the procedure for presumed recurrence of cancer. Potency (defined as an erection sufficient to complete intercourse to the satisfaction of the patient) was maintained in 4 of 9 patients, and the other 5 were potent with phosphodiesterase 5 inhibitors (PDE5I) or intracavernosal injection

(ICI) (table 1). No instances of other complications previously described with cryoablation such as obstruction, incontinence, penile numbness, or fistula formation occurred.

DISCUSSION

“Nerve-sparing” cryoablation of the prostate is an attempt to combine the advantages of cryoablation, that of excellent treatment of extracapsular extension⁹⁻¹⁰ and low general morbidity, while preserving the patient’s erectile function. To destroy extracapsular cancer extension, freezing was extended more than 4 mm beyond the capsule. A normal saline injection into Denonvilliers fascia to separate the rectum from the prostate facilitated aggressive freezing on the side of the cancer. This method showed successful local cure of cancer, with no local recurrence in any of the patients at last follow-up. Three of 9 patients had T2 disease, 4 patients had Gleason grade 7, and 2 patients had PSA levels of 10 ng/mL or greater (table 1). Defining a successful result is difficult in terms of cancer recurrence with cryoablation. However, the author expects PSA stability (i.e., no rise in PSA over time) in patients adequately treated as in patients without prostate cancer. The author defines PSA stability as no rise in the PSA level on two consecutive results, and defined biochemical failure according to recommendations of the RTOS-ASTRO Phoenix Consensus Conference.¹¹ This is consistent with common-sense clinical practice and has resulted in none of the patients treated to date needing additional treatment for recurrence of cancer. To decide the extent of disease in prostate cancer, traditional ultrasonography and magnetic resonance imaging are inadequate. This result shows systematic biopsy as the major tool for preoperative decision of the extent of disease. The usual sextant

biopsy showed a false-negative rate approaching 25%.¹² However, results of optimization biopsy using a second set of biopsies and improved gland sampling can diminish the chances of missing a significant multifocal tumor.¹³ In this study, the author also used the optimization biopsy of 12 sites of prostate, and their cancer findings were crucial to decision of the site of nerve sparing cryoablation. Six of the patients the author treated were younger than 60 years, a group in whom inadequate treatment could have an impact on survival theoretically. This fact should be accounted when considering a wider application of this procedure, as it should be with other potency-sparing procedures. Cryoablation has the special ability to allow repeated procedure without increased morbidity unlike nerve-sparing RP and brachytherapy.⁸ The cryoablation appears to have extremely low morbidity. No significant blood loss or perioperative/postoperative pulmonary or cardiac complications occurred. In author's cases, no one had urinary incontinence after cryoablation. It was reported that incontinence occurred less than 2% of patients in total gland cryoablation.⁸ Therefore incontinence after cryoablation would be expected to be negligible. This is a positive secondary effect of nerve sparing cryoablation to improve potency, because nerve-sparing RP reports 6% of incontinence rates.³ Of 9 patients treated, 4 remained potent (and the other 5 are potent with PDE5I or ICI), with all potent patients satisfied with their sexual functioning. Nonetheless, this study was a retrospective result, without using standard sexual functioning questionnaires, and investigator's bias, as well as patient inclination to please the treating surgeon, should be regarded a possible factor affecting the results. In the future, the evaluation for potency had to be performed through the valid questionnaires such as IIEF questionnaire. Five patient required PDE5 inhibitors or injection therapy postoperatively to meet success definition. The

data on nerve-sparing RP show a significant decrease in potency rates when one NVB is spared compared with two.^{2,3} But in this report the author cannot show any differences between unilateral and bilateral nerve sparing cryoablation because of small number of patients. Achieving high potency rates by nerve sparing cryoablation, without risking a positive margin on the tumor side, is an advantage of this procedure compared with nerve-sparing RP. Nerve sparing cryoablation may explain the superior results by cryoablation's minimal vascular disruption or the lack of nerve manipulation and trauma compared with RP. Potency rates in nerve-sparing RP are often reported 18 months after RP. All patients had returned erectile function within 1 year of the cryoablation. The rapidity of return is related to preoperative hormonal treatment and the extent of freezing. All of the patients showed impotence after the cryoablation in the short term, and a long period was needed to recover potency in some patients. Nerve-sparing cryoablation seems to have advantages over brachytherapy and external beam radiotherapy, as well. Unlike brachytherapy, which is limited to patients with low-volume, low Gleason grade disease, cryoablation does not limited to other clinical parameters. Radiotherapy does not to maintain its initial potency advantage in the long term follow up. After 2 years, potency rates are almost the same with those after nerve-sparing RP.¹⁴ The complications after brachytherapy can have a adverse impact on patient QOL.¹⁵ The author's procedure had eliminated rectal complications, which are major concerns with radiotherapy, by separation of the rectum and prostate with saline injection into Denonvilliers fascia before freezing. Moreover, brachytherapy patients who have local failure have limited available options. Finally, a major disadvantage of radiotherapy is that patients with failed radiation show a significant increase in Gleason grade and aggressiveness of cancer in the recurrent

cancer.¹⁶ Certainly, radiotherapy is not a favorable option in a procedure possibly being applied to younger patients compared to nerve sparing cryoablation. This study also showed that after cryoablation a QOL is sustained when compared to other treatments. On the basis of these strengths, the author believes that an attempt to improve sexual function after cryoablation is feasible.

Nerve-sparing cryoablation, in which one or two neurovascular bundle is spared, showed the possibility of preserving potency in most patients without compromising cancer control. These preliminary results warrant further study.

REFERENCES

- Walsh PC, and Donker PJ. Impotence following radical prostatectomy: insight into etiology and prevention. *J Urol* 1982;128:492-5.
- Talcott JA, Reiker P, Propert KJ, Clark JA, Wishnow KI, Loughlin KR, et al. Patient reported impotence and incontinence after nerve-sparing radical prostatectomy. *J Natl Cancer Inst* 1989;16:1117-23.
- Ficarra V, Novara G, Ahlering TE, Costello A, Eastham JA, Graefen M, et al. Systematic review and meta-analysis of studies reporting potency rates after robot-assisted radical prostatectomy. *Eur Urol* 2012;62:418-30.
- Wahle S, Reznicek M, Fallon B, Platz C, Williams R. Incidence of surgical margin involvement in various forms of radical prostatectomy. *Urology* 1990;36:23-6.
- Vaidya A, Hawke C, Tiguert R, Civantos F, Soloway M. Intraoperative T staging in radical retropubic prostatectomy: is it reliable? *Urology* 2001;57:949-54.
- Bonney WW, Fallon B, Gerber WL, Hawtrey CE, Loening SA, Narayana AS, et al. Cryosurgery in prostatic cancer survival. *Urology* 1982;14:37-42.
- Onik GM, Cohen K, Reyes GD, Rubinsky B, Chang Z, Baust J. Transrectal ultrasound-guided percutaneous radical cryosurgical ablation of the prostate. *Cancer* 1993;72:1291-9.
- Wong WS, Chinn DO, Chinn M, Chinn J, Tom WL, Tom WL. Cryosurgery as a treatment for prostate carcinoma: results and complications. *Cancer* 1997;79:963-74.
- Robinson JW, Donnelly BJ, Saliken JC, Weber BA, Ernst S, Rewcastle JC. Quality of life and sexuality of men with prostate cancer 3 years after cryosurgery. *Urology* 2002;60:12-8.
- Onik G, Narayan P, Vaughan D, Dineen M, Brunelle D. Focal "nerve-sparing" cryosurgery for treatment of primary prostate cancer: a new approach to preserving potency. *Urology* 2002;60:109-14.
- Roach M 3rd, Hanks G, Thames H Jr, Schellhammer P, Shipley WU, Sokol GH, et al. Defining biochemical failure following radiotherapy with or without hormonal therapy in men with clinically localized prostate cancer: recommendations of the RTOG-ASTRO Phoenix Consensus Conference. *Int J Radiat Oncol Biol Phys* 2006;65:965-74.
- Villers A, McNeal JE, Freiha FS, Stamey TA. Multiple cancers in the prostate: morphologic features of clinically recognized vs. incidental tumors. *Cancer* 1992;70:2312-38.
- Cookson MS. Update on transrectal ultrasound guided needle biopsy of the prostate. *Mol Urol* 2000;4:93-7.
- Sanchez-Ortiz RF, Broderick GA, Rovner ES, Wein AJ, Whittington R, Malkowicz SB. Erectile function and quality of life after interstitial radiation therapy for prostate cancer. *Int J Impot Res* 2000;12:S18-24.
- Zelevsky MJ, Hollister T, Raben A, Matthews S, Wallner KE. Five year biochemical outcome and toxicity with transperineal CT-planned permanent I-125 prostate implantation for patients with localized prostate cancer. *Int J Radiat Oncol Biol Phys* 2000;47:1261-6.
- O'Sullivan DC, Barrett DM, Colby TV, Lieber MM, Cupps RE. Effect of external beam radiation therapy on prostatic carcinoma DNA content as measured by static image cytometry. *Eur Urol* 1992;21:235-59.