

## A Case of Retrospective Four-dimensional Computed Tomography for Gated Radiotherapy

Sangwook Lim · Sun Young Ma · Tae Sig Jeung

*Department of Radiation Oncology, Kosin University College of Medicine, 34 Amnam-dong, Seo-gu, Busan 602-702, Korea*

### Abstract

To introduce the four-dimensional computed tomography (4DCT, Light Speed RT, General Electric, USA) scanner newly installed in our department and to evaluate its advantage over conventional CT for radiation therapy. Respiratory signal measured by real-time position management (RPM<sup>®</sup>, Varian Medical Systems, USA) was recorded in synchronization with the 4DCT scanner. 4DCT data were acquired in axial cine mode and sorted retrospective image based on respiratory phase. Planning target volumes (PTVs) delineated from helical CT and 4DCT images were compared.

The PTV delineated from conventional helical CT images was 2 cc larger than that from 4DCT images. Dose in PTV of the plan from retrospective CT was 99.3% (minimum=72.0%, maximum=106.5%) and that of helical CT plan was 95.2% (minimum=24.1%, maximum=106.4%) of prescribed dose.

The minimum doses in PTV for helical CT plan and 4DCT plan were calculated to 24.1% and 72.0% of prescribed dose, respectively. It shows that the uniformities were significantly improved by using 4CDT.

Conclusion: Comparing with dose volume histograms (DVHs) of both plans, the coverage for 4CDT plan was 3.7% improved. It is expected that 4DCT could improve tumor control and reduce radiation toxicity for liver cancer in radiation therapy.

**Key words** : Four dimensional CT, Retrospective CT, Gated radiotherapy

## INTRODUCTION

Organ motion due to respiration is known to substantially affect radiation treatment of thoracic and abdominal region. During respiration, tumors in lung and liver typically move up to 4 cm<sup>1)</sup> and large volume of normal tissue is irradiated. Therefore, a generous margin according to respiratory motion should be considered. Although respiratory target motion differs depending on the patients and the sites, conventionally planning target volume (PTV) is delineated with 1 cm margin in craniocaudal direction around the target in the lung.

To take account into organ motion explicitly in treatment planning and delivery, time-resolved CT data acquisition is needed<sup>2)</sup>. Recently, a 4-slice CT scanner became available and allowed for four-dimensional (4D) CT or

respiration-correlated CT scans to be performed<sup>3)</sup>. This study introduces the 4DCT (Light Speed RT, General Electric, USA) newly installed in our department and evaluate its feasibility for gated radiotherapy.

## CASE REPORT

A liver cancer patient was selected, whose target was located in right upper lobe of liver. The patient was instructed to breathe freely during the CT scan. Prior to CT scanning, patient's respiration cycle was monitored until it was stable. Both helical CT and 4DCT images data were acquired with slice thickness of 2.5 mm. 4DCT data were acquired by CT scanner with 4 channels in an axial cine mode and a helical mode, respectively.

Motion phases were recorded by real-time position management (RPM<sup>®</sup>, Varian Medical Systems, USA) in synchronization with the x-ray "on" signal from the CT scanner when 4DCT data were being gathered. Since

교신저자 : 임 상 욱  
주소 : 602-702 부산광역시 서구 압남동 34번지  
고신대학교 의과대학 방사선종양학교실  
TEL : 051-990-6393  
E-mail : slim@kosin.ac.kr

respiratory signal was digitally stamped on each CT slice, it was possible to reconstruct CT slices retrospectively at several phases over respiratory cycle, yielding a 4D dataset. The 4DCT dataset were sorted out for 10 phase of motion in percent within the respiratory cycle by 4DCT software. As shown Fig. 1, 0% corresponds to end-inhalation and 50% to end-exhalation. In this study 30%, 40%, 50%, 60%, and 70% phases of respiration were selected for retrospective image sorting.

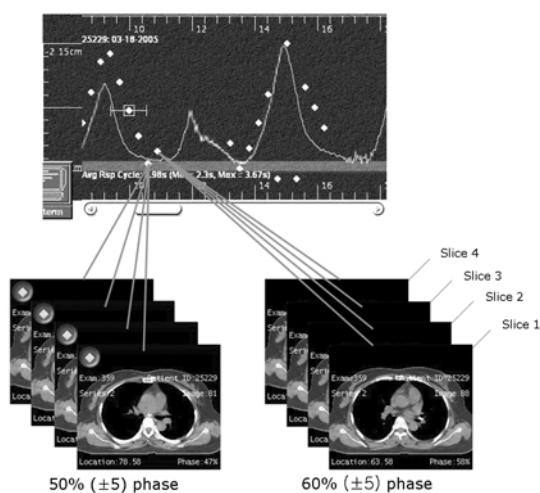


Fig. 1. 4DCT images were sorted based on each phase, which divided into 10 phase groups. The slice thickness was 2.5 cm.

Both helical CT images and retrospective CT images were transported to treatment planning system (TPS). TVs were delineated from helical CT images and retrospective CT images with 1 cm PTV margin for helical CT and 0.5 cm for retrospective CT, respectively. Dose volume histograms (DVHs) for both plans were calculated and compared.

## DISCUSSION

Total number of 4DCT images were 484 slices and separated according to 10 phases in percent with  $\pm 5\%$  tolerance. The average patient's respiratory cycle was measured 2.98 second (minimum=2.3 s, maximum=3.67 s). Fig. 2 shows the coronal view of 4DCT images assorted by organ positions depending on phases. Organ motion due to respiration was measured 1.5 cm in craniocaudal direction

in this case by measuring the displacement of diaphragm between 0% phase (end-inhalation) and 50% phase (end-exhalation). The PTV delineated from conventional helical CT images was 2 cc larger than that from 4DCT images. Dosein PTV of the plan from retrospective CT was 99.3% (minimum=72.0%, maximum=106.5%) and that of helical CT plan was 95.2% (minimum=24.1%, maximum=106.4%) of prescribed dose. Comparing with DVHs of both plans, the dose coverage for 4CDT plan was improved as much 3.7% (Fig. 3).

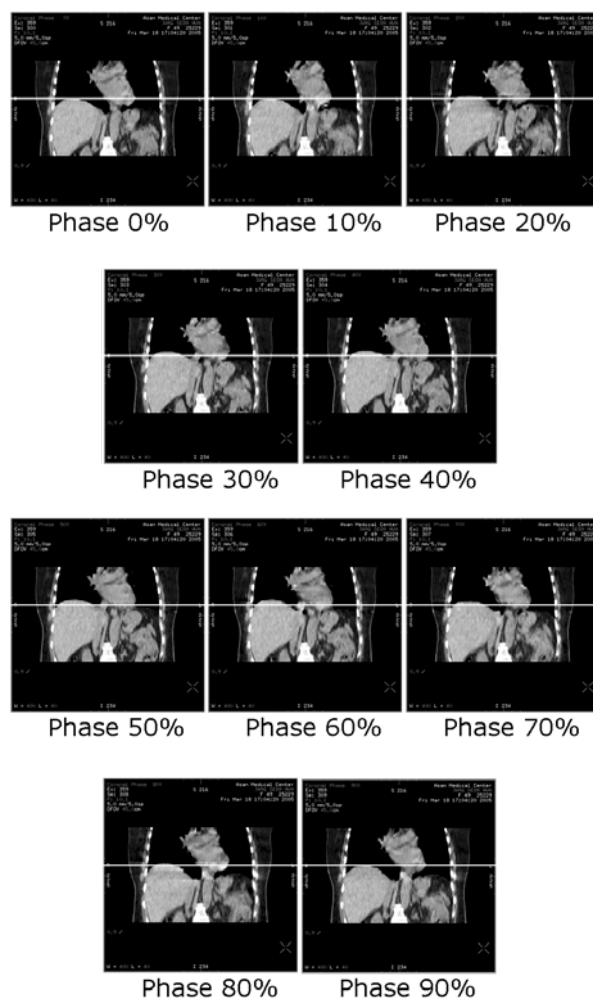


Fig. 2. Coronalview of 4DCT images sorted at different phase of respiration: it was separated into 10 positions of the diaphragm while moving as imaged with 4DCT. Motion range was measured 1.5 cm in craniocaudal direction. The 30 ~ 70% ( $\pm 5\%$ ) phases were selected for reconstructing retrospective CT.

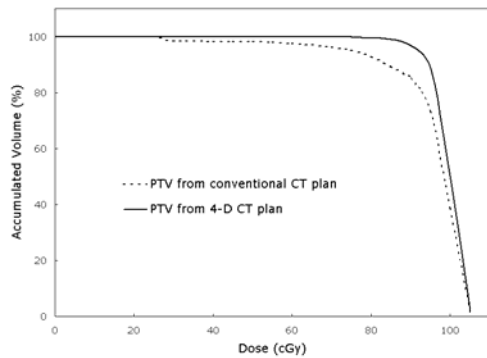


Fig. 3. Comparison of DVH, calculated from conventional CT plan and 4DCT plan for the same patient: The maximum accumulated volumes for each plan were normalized to 100%. Comparing to the conventional method, the DVH was calculated 3.7% larger.

Conventionally, slow scanning techniques has been used to obtain CT data including target motion and routine margin has been considered for moving target. 4DCT and RPM<sup>®</sup> enabled gated treatment planning and delivery, which could effectively improve target coverage. The minimum doses in PTV for helical CT plan and 4DCT plan were calculated to 24.1% and 72.0% of prescribed dose, respectively. It shows that the uniformities were significantly improved by using 4DCT.

We have to compromise between the treatment time and the accuracy, when we select phases for retrospective CT. Backprojected densities could be smeared out in moving direction according to the tolerance of the respiratory phase. Since respiratory cycle and motion differ from patients and target location, appropriate phase and tolerance selection required.

It is expected that 4DCT could improve tumor control and reduce radiation toxicity for liver cancer in radiation therapy.

## 국문초록

새로 도입된 사차원 컴퓨터 단층촬영 장치를 소개하고 기존의 CT와 비교하여 방사선치료에 있어서의 장점을 평가하고자 한다. RPM으로 측정된 호흡신호는 사차원 CT와 연동되어 저장된다. 사차원 CT 영상은 시간별로 단층촬영되며 호흡 위상별로 분류된다. 기존의 CT 영상과

사차원 CT 영상에서 각각 PTV를 그려 비교하였다. 기존의 CT 영상에서 그린 PTV는 사차원 CT에서 그린 것에 비하여 크기가 약 2 cc 가 컸다. PTV의 선량은 사차원 CT를 이용하여 치료계획한 경우 처방선량의 99.3% 였으며, 기존의 CT를 이용한 경우는 95.2%로 유의한 차이가 났다. 두 치료계획에서 DVH를 비교한 결과 치료범위가 사차원 CT에서 3.7% 개선되었다. 사차원 CT는 방사선치료에 있어서 치료성적을 올리고 방사선 부작용을 줄일 수 있을 것이라 기대된다.

## REFERENCES

- 1) Mageras GS, Pevsner A, Yorke ED, et al.: Measurement of lung tumor motion using respiration-correlated CT. *Int J Radiat Oncol Biol Phys* 60:933-941, 2004
- 2) Rietzel E, Pan T, Chen GTY: Four-dimensional computed tomography: Image formation and clinical protocol. *Med Phys* 32:874-889, 2005
- 3) Underberg RWM, largerwaard FJ, Cuijpers JP et al.: Four-dimensional CT scans for treatment planning in stereotactic radiotherapy for stage I lung cancer. *Int J Radiat Oncol Biol Phys* 60:1283-1290, 2004